

Cutaneous onchocerciasis (AlSawda) in Republic of Yemen

Mohammed Abdul Qader, Mohammed AlMalmi

Corresponding author

Mohammed Abdul Qader Almalmi MD, consultant and specialist of dermatology, Venereology and aesthetic medicine in doctor AlMalmi medical clinic Sanaa Yemen and Be you Clinics UAE

Email : maqma1952@gmail.com

Phone : 009671226713 ; 00971501244573

Received Date : Jan 09, 2023

Accepted Date : Jan 11, 2023

Published Date : Feb 10, 2023

Abstract

Background : Onchocerciasis is an infection caused by the nematode *Onchocerca volvulus*. Humans acquire onchocerciasis through the bite of *Simulium* blackflies. Because the fly develops and breeds in flowing water, onchocerciasis is commonly found along rivers and is sometimes referred to as river blindness.

Objective : This study was to identify the skin pigmentary disorder and parasitic skin manifestation in Yemeni patients.

Patients and methods : Seven male Yemeni patients 25 to 40 age presented with severe pruritus papular lichenification, loss of skin elasticity, atrophy, and/or depigmentation skin lesions localized in the unilateral of one lower limb and buttock. The duration was ranged from one to two years. Skin examination in patients with onchocerciasis may reveal subcutaneous nodules, diffuse onchodermatitis, lymphedema, and/or atrophic changes. Sowda refers to severe pruritus and darkened skin, usually confined to one limb. Lymphadenopathy occur. No ocular involved. Skin snip procedure was positive. Skin biopsy and histopathological findings were diagnostic.

Results : The clinical data and the investigations revealed that the seven cases were cutaneous onchocerciasis.

Conclusion : Cutaneous onchocerciasis is a quite skin disease in Republic of Yemen. It is sporadic in some areas Al Mahweet and Sharaab. The local name of this disease Sowda mains darkness of the skin.

Keywords : Yemen , republic , onchocerciasis , cutaneous.

Introduction and epidemiology

Onchocerciasis is a chronic and progressive skin, eye, and neurological disease caused by *Onchocerca volvulus*, a filarial nematode (worm). The eye disease is often called river blindness. Over 90% of cases of onchocerciasis occur in 31 countries in sub-Saharan Africa; the remainder are found in Latin America, and Yemen in the Arabian Peninsula. According to the WHO, onchocerciasis has been eradicated from Columbia, Ecuador, Guatemala, and Mexico but persists in the Amazon region of Brazil and Venezuela. Of the 218 million people who live in endemic areas, at least 18 million are currently infested; 4 million have a skin disease, and 2 million are blind or visually impaired. Initial infestation may occur in childhood and produce no symptoms for long periods. However the neurological manifestations mainly affect children. Short-term travellers to endemic areas are at low risk of onchocerciasis, as multiple bites are required for infestation. Travellers who visit endemic areas for extended periods and live or work near blackfly habitats are at greatest risk of infection. *O. volvulus* is transmitted to humans through the bite of a female blackfly (*Simulium* spp). Blackflies are found near fast-flowing rivers and streams in the inter-tropical zones, and bite during the day. In humans, the adult worms live in nodules scattered under the skin. The female worm produces millions of larval worms (microfilariae). Microfilariae migrate through the lymphatic system under the skin and are ingested by blackflies during a blood meal. The larvae mature in the blackfly over the next two weeks. When the blackfly bites another human, the larvae enter through the wound, penetrate the tissues, and develop into adult worms. A female worm can live for up to 15 years and produce hundreds of microfilariae each day. The microfilariae mature over 2 to 3 years, and their death releases symbiotic *Wolbachia* bacteria causing an inflammatory reaction in the skin and eye. Years of exposure may lead to skin disfigurement and irreversible blindness. (figures 1,2). (1,2,3,4,5,6,7,8,9,10)

Discussion

Six skin disease patterns have been described. Two or more patterns may be present in a single patient, and the patterns may evolve and change over time. Acute papular onchodermatitis Widespread itchy eczema-like rash with multiple small itchy papules which progress to become vesicles and pustules. The face, trunk, and extremities

are often affected. Chronic papular onchodermatitis Severely itchy rash with scattered flat-topped papules and areas of hyperpigmentation. The shoulders, buttocks, and extremities are typically affected. The most common pattern of skin disease. Lichenified onchodermatitis Large areas of wrinkled thin, dry inelastic skin. Commonly affects buttocks and lower back. Onchocercal depigmentation Also called "leopard skin". Areas of pigment loss (leukoderma), with islands of normally pigmented skin surrounding hair follicles. Often affects the shins in a symmetrical pattern and is not usually itchy. Palpable onchocercal nodules (oncocercoma) Subcutaneous lumps found over bony prominences contain the adult worms. The subcutaneous nodules range in size from a few millimetres to several centimetres, and each contains 2 to 4 adult worms that can reach a length of 80 cm. (figures 3,4,5,6,7,8,9). Identifying microfilariae in six skin snips dropped into normal saline and examined microscopically. In early or mild disease when larvae are not seen, polymerase chain reaction (PCR) is used to amplify the larval DNA. Adult worms are seen in excised nodules under a light microscope. Microfilariae may be directly observed during slit lamp examination of the eye. Detection of antibodies against *O. volvulus* in blood samples – however, this test cannot reliably distinguish between past and present infection so is used for diagnosing patients with a brief exposure history. (Figures 10,11,12,13,14,15). (11,12,13,14,15,16,17,18,19) It is prevent by No vaccine available. Vector control using DDT or temephos to eliminate blackflies. Mass ivermectin dosing every six months to interrupt the worm life cycle Prevent blackfly bites. Use of insect repellents such as. DEET. Wearing long-sleeved shirts and pants. Wear permethrin-impregnated clothing.(20,21,22,23,24,25,26). Oral ivermectin kills the microfilariae but not the adult worm. One dose every 3 months is required. Doxycycline targets the Wolbachia bacteria and is used in combination with ivermectin..New agents under investigation to kill the adult worm include suramin and moxidectin. Onchocerciasis has been successfully eradicated from some countries and programmes continue in many others. Treatment of established infestation is not curative, but aims to stop progression of disease. Prevention is the most cost-effective measures. The cutaneous of onchocerciasis in Yemen is quite involve the skin not the eyes. (27,28,29,30,31,32,33,34,35).

Figure 1: Simulium fly (black fly).

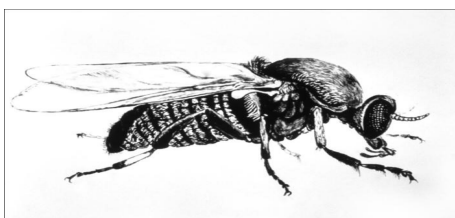


Figure 2 : Simplified life cycle of *Onchocerciasis volvulus*

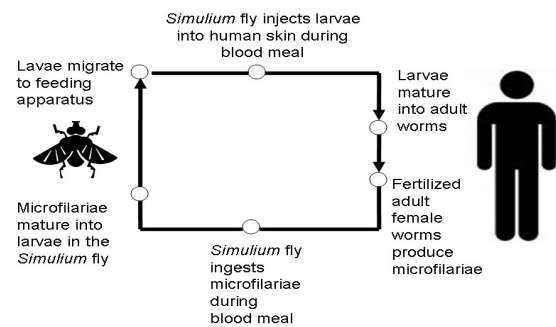


Figure 3 : papular pruritus lichenification depigmentation skin lesions localized in the unilateral of right lower limb.

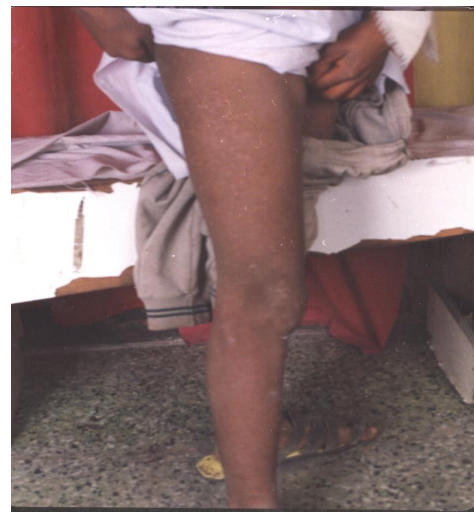

Figure 4 : papular pruritus lichenification depigmentation skin lesions localized in the unilateral left buttock. (onchodermatitis)

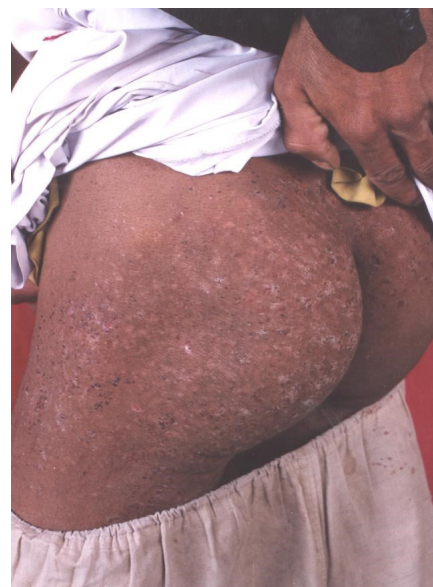

Figure 5 : papular pruritus lichenification depigmentation skin lesions localized in the unilateral of right lower limb (onchodermatitis)

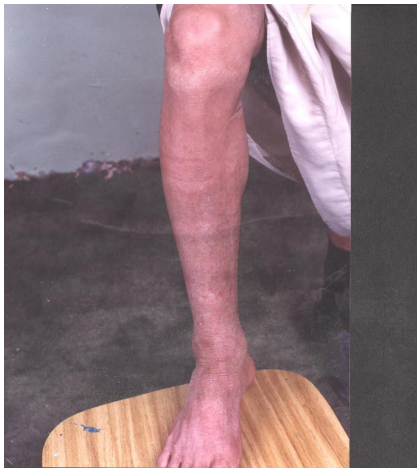


Figure 8 : onchodermatitis with slight lymphoedema of left lower limb.

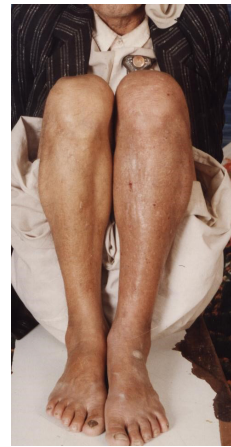

Figure 6 : onchodermatitis with lymphodema of left lower limb.

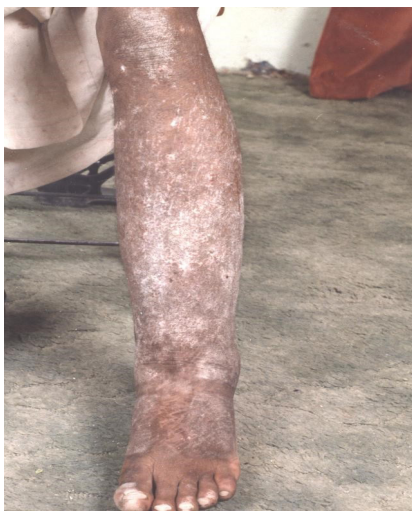

Figure 9 : onchodermatitis with lymphoedema of the left lower limb

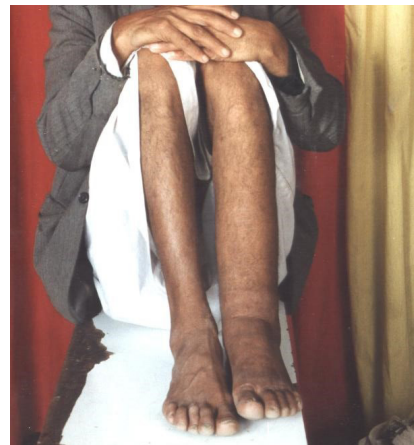

Figure 7 : onchodermatitis with femoral lymphoadenopathy in right lower limb

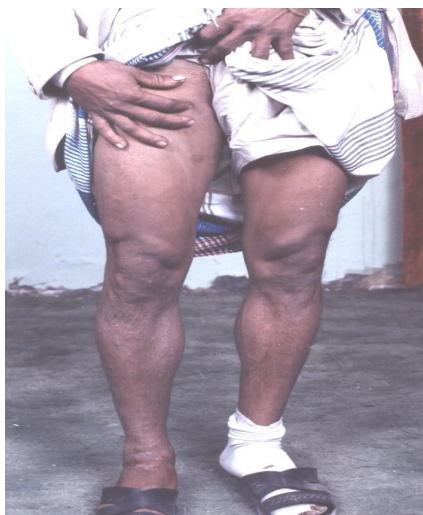

Figure 10 : Skin snip showed microfilaria in saline with slide

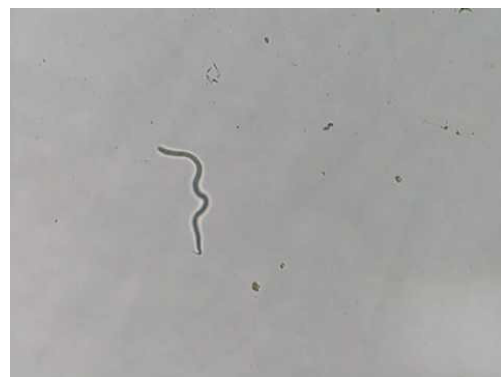

Figure 11 : Skin snip showed microfilaria in saline with slide high magnification.

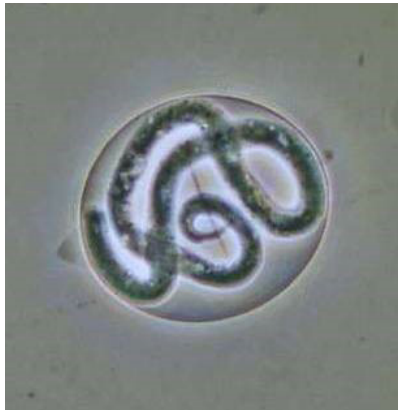

Figure 12: In early untreated cases, tissue biopsy samples may show a mild chronic inflammatory infiltration; eosinophils, lymphocytes, and histiocytes may surround the microfilariae. Microfilariae are often present without a surrounding cellular reaction

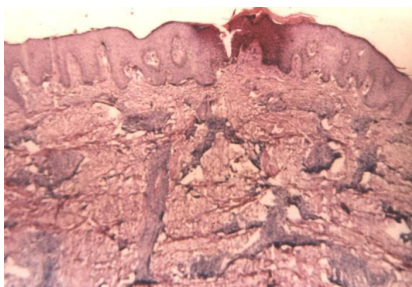


Figure 13 : Later cases show hyperkeratosis, parakeratosis, tortuous dermal vessels, dilated lymphatics, and pigment incontinence. An increased number of dermal fibroblasts leads to perivascular fibrosis. In more advanced cases, hyalinized scar tissue replaces the collagen and elastic fibers in the dermis.

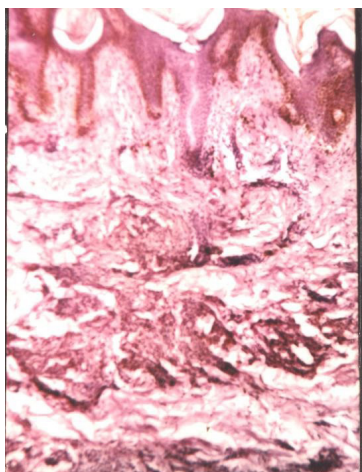


Figure 14 : Later cases show hyperkeratosis, parakeratosis, tortuous dermal vessels, dilated lymphatics, and pigment incontinence. An increased number of dermal fibroblasts leads to perivascular fibrosis. In more advanced cases, hyalinized scar tissue replaces the collagen and elastic fibers in the dermis.

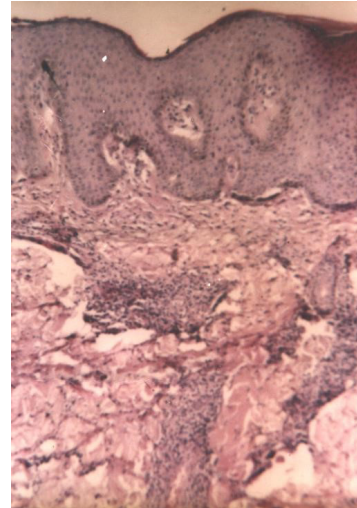
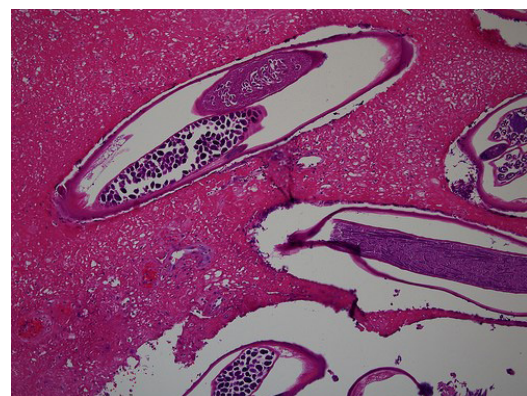

Figure 15 : The microfilariae have pointed tails, elongated posterior nuclei, paired anterior nuclei, and large spaces between the tip or tail and the first nuclei. They lack sheaths. Onchocercomas are made up of an outer vascular fibrous stroma embedded with groups of perivascular leukocytes. The inner layer is composed of hyaline connective tissue intermingled with coiled adult worms. A dense cellular infiltrate composed of eosinophils, lymphocytes, macrophages, and giant cells surrounds the worm. The coiled appearance of the worm, the presence of microfilaria in gravid females, and the presence of a gut help in identifying the worm. Photomicrograph of a skin biopsy specimen from a patient with onchocerciasis. A worm is shown in cross-section.



References

1. Amazigo U. The African Programme for Onchocerciasis Control (APOC). *Ann Trop Med Parasitol*. Sep 2008;102 Suppl 1:19-22.
2. Ayong LS, Tume CB, Wembe FE, Simo G, Asonganyi T, Lando G. Development and evaluation of an antigen detection dipstick assay for the diagnosis of human onchocerciasis. *Trop Med Int Health*. Mar 2005;10(3):228-33.
3. Basáñez MG, Pion SD, Boakes E, Filipe JA, Churcher TS, Boussinesq M. Effect of single-dose ivermectin on *Onchocerca volvulus*: a systematic review and meta-analysis. *Lancet Infect Dis*. May 2008;8(5):310-22.
4. Boatin B. The Onchocerciasis Control Programme in West Africa (OCP). *Ann Trop Med Parasitol*. Sep 2008;102 Suppl 1:13-7.
5. Boatin BA, Toé L, Alley ES, Dembélé N, Weiss N, Dadzie KY. Diagnostics in onchocerciasis: future challenges. *Ann Trop Med Parasitol*. Apr 1998;92 Suppl 1:S41-5.
6. Burnham G. Onchocerciasis. *Lancet*. May 2 1998;351(9112):1341-6.
7. Dimomfu BL, Lubeji DK, Noma M, Sékétéli A, Boussinesq M. African Programme for Onchocerciasis Control (APOC): sociological study in three foci of central Africa before the implementation of treatments with ivermectin (Mectizan). *Trans R Soc Trop Med Hyg*. Jul 2007;101(7):674-9.
8. Enk CD. Onchocerciasis--river blindness. *Clin Dermatol*. May-Jun 2006;24(3):176-80.
9. Guzmán GE, Lavebratt C, Luján R, Akuffo H. Diagnosis of onchocerciasis using highly specific and sensitive native proteins. *Scand J Infect Dis*. 2002;34(8):583-90.
10. Hoerauf A, Büttner DW, Adjei O, Pearlman E. Onchocerciasis. *BMJ*. Jan 25 2003;326(7382):207-10.
11. Hoerauf A, Mand S, Adjei O, Fleischer B, Büttner DW. Depletion of wolbachia endobacteria in *Onchocerca volvulus* by doxycycline and microfilaridermia after ivermectin treatment. *Lancet*. May 5 2001;357(9266):1415-6.
12. Hoerauf A, Mand S, Volkmann L, Büttner M, Marfo-Debrekyei Y, Taylor M, et al. Doxycycline in the treatment of human onchocerciasis: Kinetics of *Wolbachia* endobacteria reduction and of inhibition of embryogenesis in female *Onchocerca* worms. *Microbes Infect*. Apr 2003;5(4):261-73.
13. Hoerauf A, Marfo-Debrekyei Y, Büttner M, Debrah AY, Konadu P, Mand S, et al. Effects of 6-week azithromycin treatment on the *Wolbachia* endobacteria of *Onchocerca volvulus*. *Parasitol Res*. Jul 2008;103(2):279-86.
14. Hoerauf A, Specht S, Büttner M, Pfarr K, Mand S, Fimmers R, et al. *Wolbachia* endobacteria depletion by doxycycline as antifilarial therapy has macrofilaricidal activity in onchocerciasis: a randomized placebo-controlled study. *Med Microbiol Immunol*. Sep 2008;197(3):295-311.
15. Hotez PJ. Control of onchocerciasis--the next generation. *Lancet*. Jun 16 2007;369(9578):1979-80.
16. Kayembe DL, Kasonga DL, Kayembe PK, Mwanza JC, Boussinesq M. Profile of eye lesions and vision loss: a cross-sectional study in Lusambo, a forest-savanna area hyperendemic for onchocerciasis in the Democratic Republic of Congo. *Trop Med Int Health*. Jan 2003;8(1):83-9.
17. Kayembe DL, Kasonga DL, Kayembe PK, Mwanza JC, Boussinesq M. Profile of eye lesions and vision loss: a cross-sectional study in Lusambo, a forest-savanna area hyperendemic for onchocerciasis in the Democratic Republic of Congo. *Trop Med Int Health*. Jan 2003;8(1):83-9.
18. Klion AD. Filarial infections in travelers and immigrants. *Curr Infect Dis Rep*. Mar 2008;10(1):50-7.
19. Lipner EM, Dembele N, Souleymane S, Alley WS, Prevots DR, Toe L, et al. Field applicability of a rapid-format anti-Ov-16 antibody test for the assessment of onchocerciasis control measures in regions of endemicity. *J Infect Dis*. Jul 15 2006;194(2):216-21.
20. Nde PN, Pogonka T, Bradley JE, Titanji VP, Lucius R. Sensitive and specific serodiagnosis of onchocerciasis with recombinant hybrid proteins. *Am J Trop Med Hyg*. May 2002;66(5):566-71.
21. Nguyen JC, Murphy ME, Nutman TB, Neafie RC, Maturo S, Burke DS. Cutaneous onchocerciasis in an American traveler. *Int J Dermatol*. Feb 2005;44(2):125-8.

22. Ozoh G, Boussinesq M, Bissek AC, Kobangue L, Kombila M, Mbina JR, et al. Evaluation of the diethylcarbamazine patch to evaluate onchocerciasis endemicity in Central Africa. *Trop Med Int Health*. Jan 2007;12(1):123-9.
23. Pion SD, Kamgno J, Demanga-Ngangue, Boussinesq M. Excess mortality associated with blindness in the onchocerciasis focus of the Mbam Valley, Cameroon. *Ann Trop Med Parasitol*. Mar 2002;96(2):181-9.
24. Reddy M, Gill SS, Kalkar SR, Wu W, Anderson PJ, Rochon PA. Oral drug therapy for multiple neglected tropical diseases: a systematic review. *JAMA*. Oct 24 2007;298(16):1911-24.
25. Rodríguez-Pérez MA, Domínguez-Vázquez A, Méndez-Galván J, Sifuentes-Rincón AM, Larralde-Corona P, Barrera-Saldaña HA, et al. Antibody detection tests for *Onchocerca volvulus*: comparison of the sensitivity of a cocktail of recombinant antigens used in the indirect enzyme-linked immunosorbent assay with a rapid-format antibody card test. *Trans R Soc Trop Med Hyg*. Sep-Oct 2003;97(5):539-41.
26. Sauerbrey M. The Onchocerciasis Elimination Program for the Americas (OEPA). *Ann Trop Med Parasitol*. Sep 2008;102 Suppl 1:25-9.
27. Specht S, Mand S, Marfo-Debrekyei Y, Debrah AY, Konadu P, Adjei O, et al. Efficacy of 2- and 4-week rifampicin treatment on the Wolbachia of *Onchocerca volvulus*. *Parasitol Res*. Nov 2008;103(6):1303-9.
28. Timmann C, van der Kamp E, Kleensang A, König IR, Thye T, Büttner DW, et al. Human genetic resistance to *Onchocerca volvulus*: evidence for linkage to chromosome 2p from an autosome-wide scan. *J Infect Dis*. Aug 1 2008;198(3):427-33.
29. Toè L, Adjami AG, Boatin BA, Back C, Alley ES, Dembélé N. Topical application of diethylcarbamazine to detect onchocerciasis recrudescence in west Africa. *Trans R Soc Trop Med Hyg*. Sep-Oct 2000;94(5):519-25.
30. Udall DN. Recent updates on onchocerciasis: diagnosis and treatment. *Clin Infect Dis*. Jan 1 2007;44(1):53-60.
31. Weil GJ, Steel C, Liftis F, Li BW, Mearns G, Lobos E. A rapid-format antibody card test for diagnosis of onchocerciasis. *J Infect Dis*. Dec 2000;182(6):1796-9.
32. World Health Organization. Onchocerciasis (river blindness). Report from the Fourteenth InterAmerican Conference on Onchocerciasis, Atlanta, Georgia, United States. *Wkly Epidemiol Rec*. Jul 29 2005;80(30):257-60.
33. World Health Organization. Onchocerciasis (river blindness). *Wkly Epidemiol Rec*. Jul 6 2001;76(27):205-10.
34. World Health Organization. Onchocerciasis (river blindness). *Wkly Epidemiol Rec*. Jul 6 2001;76(27):205-10.
35. World Health Organization. Onchocerciasis and its control. Report of a WHO Expert Committee on Onchocerciasis Control. *World Health Organ Tech Rep Ser*. 1995;852:1-104.